BOTULINUM TOXIN TREATMENT OF SIALORRHEA IN CHILDREN

C. Foresti**, A. Stabile°

** U.O.S. Clinical Neurophysiology, U.O.C. Neurology, ASST Papa Giovanni XXIII, Bergamo, Italy*

° Department of Neurology, San Gerardo Hospital ASST Monza, Italy

Background

Sialorrhea, or excessive salivation and drooling, is due to the loss of coordination of the muscles involved in swallowing. This causes a continuous flow of saliva outside the mouth. It is quite frequently associated with some neurological disorders in adults, such as motor neuron diseases, Parkinson's disease, brainstem injuries secondary to stroke, tumor, or trauma. Sialorrhea also affects an important subset of the pediatric population, in particular, children with cerebral palsy or hereditary neuromuscular diseases.

Botulinum toxin exerts a well-known anticholinergic effect in neuronal termination and produces temporary chemodenervation. Acetylcholine (ACh) is the chemical mediator of the neuromuscular junction, so the principal effect of botulinum toxin is to reduce muscular strength. Moreover, ACh is a neuromodulator, for a large portion of the autonomic nervous system, so the clinical use of botulinum toxin has been extended to dysautonomic disease, like hyperhidrosis and sialorrhea.

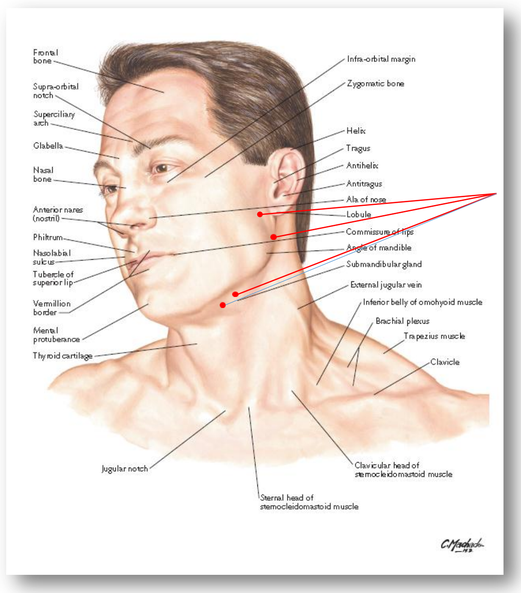

Anatomical landmarks for Botulimum injections

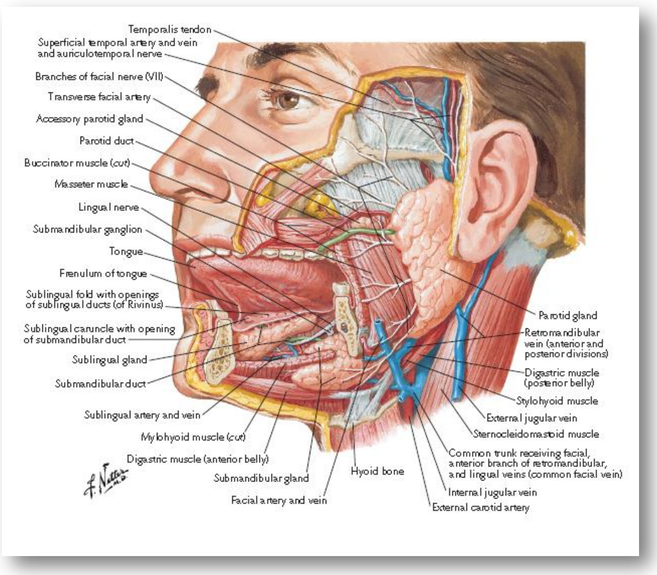

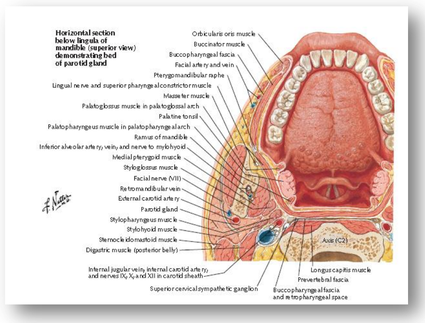

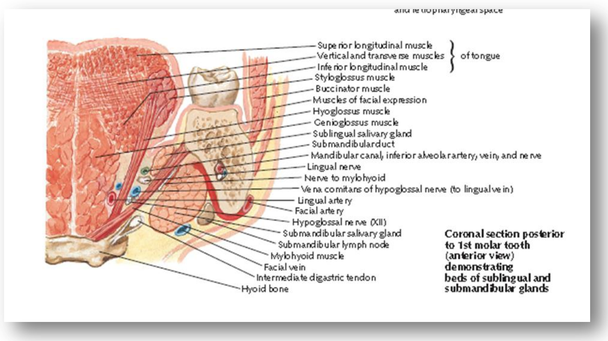

Patients

From January 2017 to date, 5 children (3 boys and 2 girls) with a severe form of spastic tetraparesis secondary to neonatal asphyxia have been included in our study. Mean age was 14 years (range: 11-17).

All children were previously on mechanical ventilation via tracheostomy and percutaneous endoscopic gastrostomy (PEG) for clinical reasons independent of sialorrhea.

In all patients, excessive salivary flow created several difficulties in patients' management and nursing, leading to skin lesions in the perioral region and, in one case, stomatological complications related to the saliva stagnation.

Possible adverse events in the use of botulinum toxin were explained to the children, parents, or legal representative and written informed consent was obtained.

Methods

During regular hospitalization, all patients received botulinum toxin injections after mild sedation with midazolam. Percutaneous injection of incobotulinum toxin A (100 UI total) into both the parotid and submandibular salivary glands was performed in all patients, with guidance from anatomic landmarks.

In particular, the parotid glands were identified in front of the anterior border of the ear, above the masseter muscle, and below the zygomatic bone; the submandibular glands (2-3 per side) were located in the middle third of the submandibular edge.

Incobotulinum toxin A was diluted with 0.9% saline solution according to a 100 U/5 mL ratio

Results

A gradual reduction in salivation was noted from the 10th day after infiltration and the maximum effect was reported from the 20th day after toxin administration.

In all patient chemodenervation of salivary glands lasted a mean period of 8 months (range 6-12). None of the patients showed adverse events related to the toxin.

Tree out of 5 patients underwent a second infiltration, which showed an efficacy and safety profile similar to the first one.

Conclusion

Botulinum toxin treatment is effective in controlling sialorrhea in children with post-anoxic cerebral palsy. The previous (for other clinical reasons) tracheostomy and PEG in all patients of our series allowed to administer botulinum toxin therapy in a controlled and safe way.

The use of ultrasound guidance may improve technical ability to set the needle in the correct position inside the salivary glands, nevertheless, this procedure may be difficult to employ in a pediatric population.

Sistema Socio Sanitario
Ospedale di Bergamo
Regione Lombardia
ASST Papa Giovanni XXIII